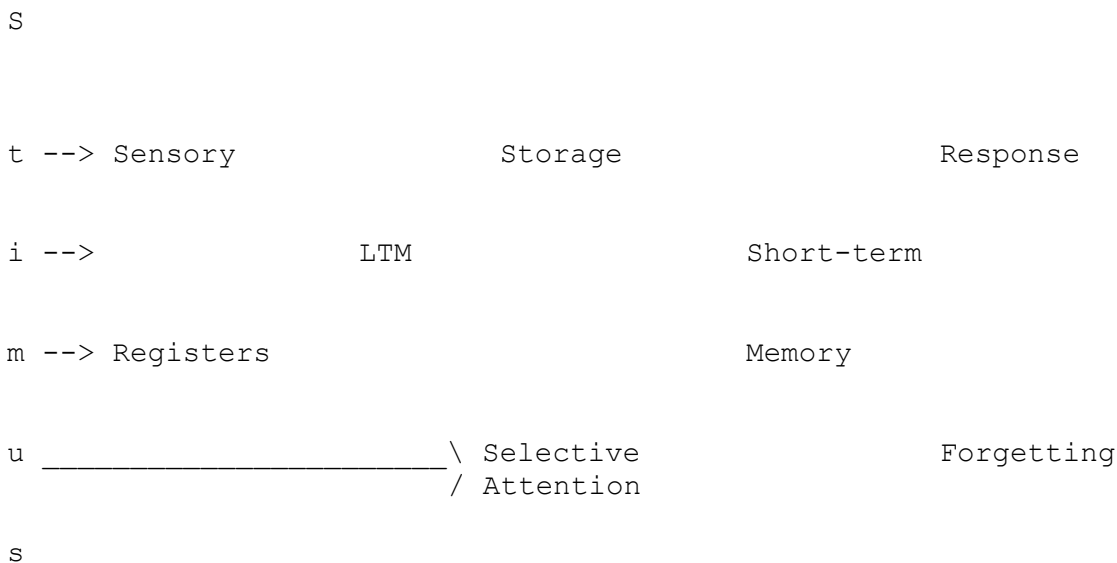


**9.65 February 23, 2004 MEMORY I: Working Memory HANDOUT** Reisberg, Ch. 5

Architecture of Memory

1. Standard model
  - a. Limited capacity
  - b. Transferring information from STM to LTM: Rehearsal theory of memory
  
2. Problems with the standard model
  - a. Rehearsal theory wrong
  - b. Depth of processing
  
3. Baddeley's Working Memory Model
  - a. Articulatory loop model
  - b. Visuo-Spatial Sketchpad

**1. Standard Memory Model:**



1. Iconic memory and other sensory memories--e.g., echoic. Very brief, close to perception itself in being very complete.
  
2. Long-term memory: Sensory information "passes through," to be identified. Doesn't result in new LTM, but passes to STM, where processing can result in new LTM. Information can be recognized fast when first encountered, but then is often forgotten.
  
3. Called STM, Working Memory, primary memory...terms used interchangeably by me.

**a. Limited capacity of STM:**

Unit of capacity in short-term memory: **Chunk**

George MILLER found that the amount you can remember of new material coming in is measured in units he called "chunks": we can remember about 7 +/- 2 such chunks in short-term memory. A chunk is a unitary concept you have already acquired: like a word, or (with unrelated letters) a letter, or any unit you already have encoded. So what constitutes a chunk varies with your experience: case of chess (pp. 464, 466 have more about chess).

Chunks can be created on the fly: as items are coming into STM. E.g., a subject at CMU who was trained until he could remember as many as 81 digits, dictated to him at 1 per second (see text p. 141 for how he did it).

ST Memory holds pointers to information in LTM: chunks or nodes in LTM.

### **b. Transferring information from STM to LTM:**

**Rehearsal theory:** the longer information is active in WM, the greater the probability that it has been stored in LTM.

Evidence:

-Serial position curve: primacy and recency

-Direct evidence for the rehearsal theory: Rundus.

## **2. Problems with the standard model**

**a. Rehearsal can be useless for LTM:** sheer time in WM not enough  
- Craik & Watkins '73 experiment (pp. 148-149)

**b. Depth/elaboration of processing** (Craik & Lockhart)

Other problems with the standard memory model included evidence that there are multiple forms of short-term memory, leading to the more general concept of "working memory" as a collection of short-lasting forms of information.


## **3. Baddeley's Working Memory Model (discussed in Ch. 1 and 5)**

Multiple forms of short-term memory:

- i. acoustic-phonological: see Articulatory Loop
- ii. imagistic/spatial: The Visuospatial Sketchpad

iii. Central Executive: everything else

**a. The Articulatory Loop Model:**



Evidence for the model:

- phonological similarity in the phonological store creates confusions and memory loss
- word length effect: memory span shorter for longer words
- unattended auditory material (especially speech) interferes with the phonological store

-articulatory suppression (la-la-la) eliminates the confusable-sounds and long-words effect for written words (while reducing memory span): it seems that articulatory suppression prevents written words from using the articulatory loop, so they have to be remembered in other ways (other parts of the memory system).

-BUT: if written words have to use the articulatory loop to get into the phonological store, how come you can judge whether words rhyme even when you are articulating something else? (unresolved aspect of the theory)

What might the Articulatory Loop be good for?

-learning a new language

-telephone dialing

-any task like mental arithmetic in which you have to keep track of verbalizable information

-but NOT necessary for most language understanding: people with an impaired "loop" due to brain injury have very short memory spans for unrelated material but are only minimally impaired in understanding speech and have normal long-term memories.

### **b. The Visuo-Spatial Sketchpad:**

The imagery system that we will discuss in detail later. Patient ELD (right hemisphere lesion).